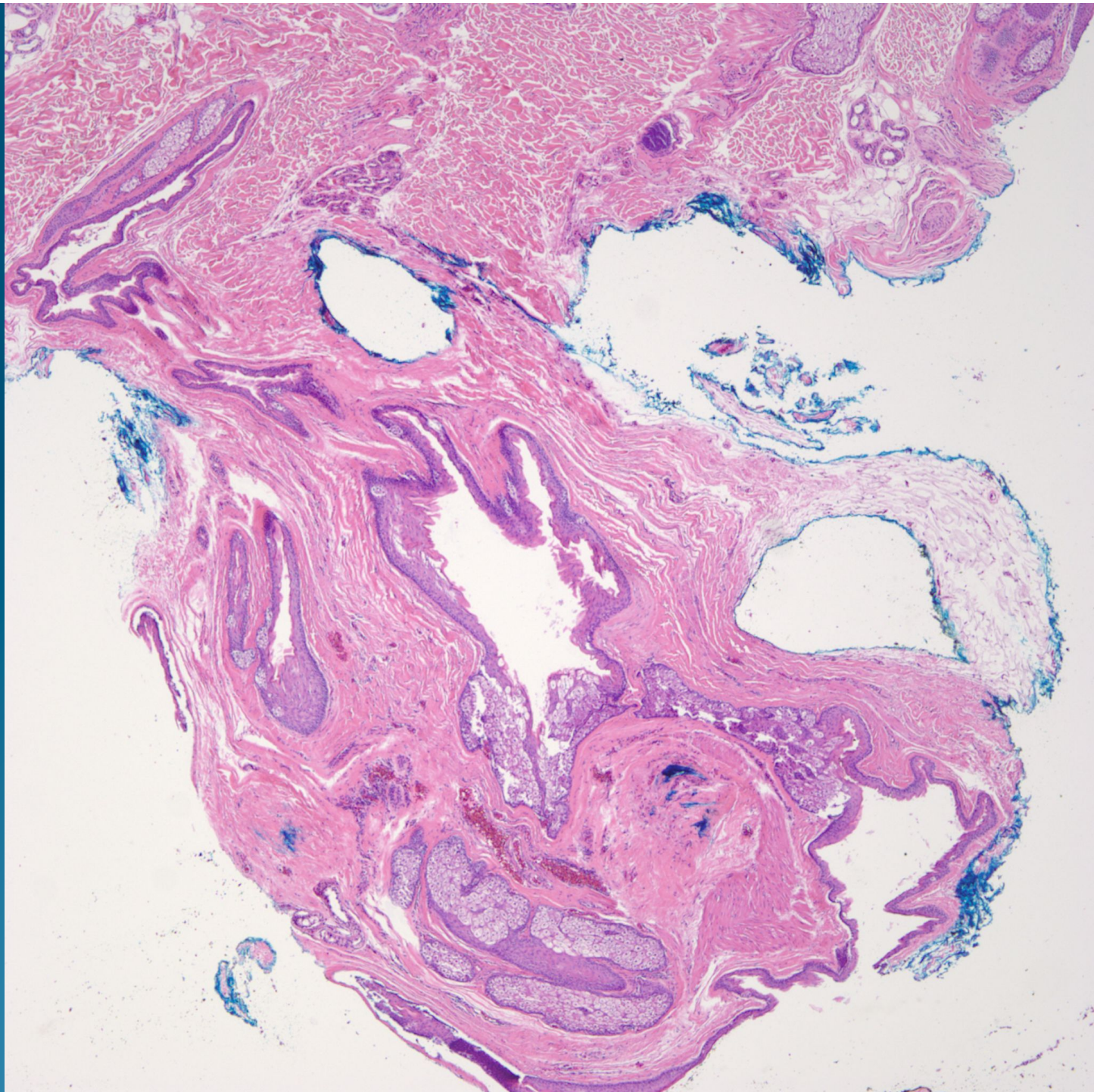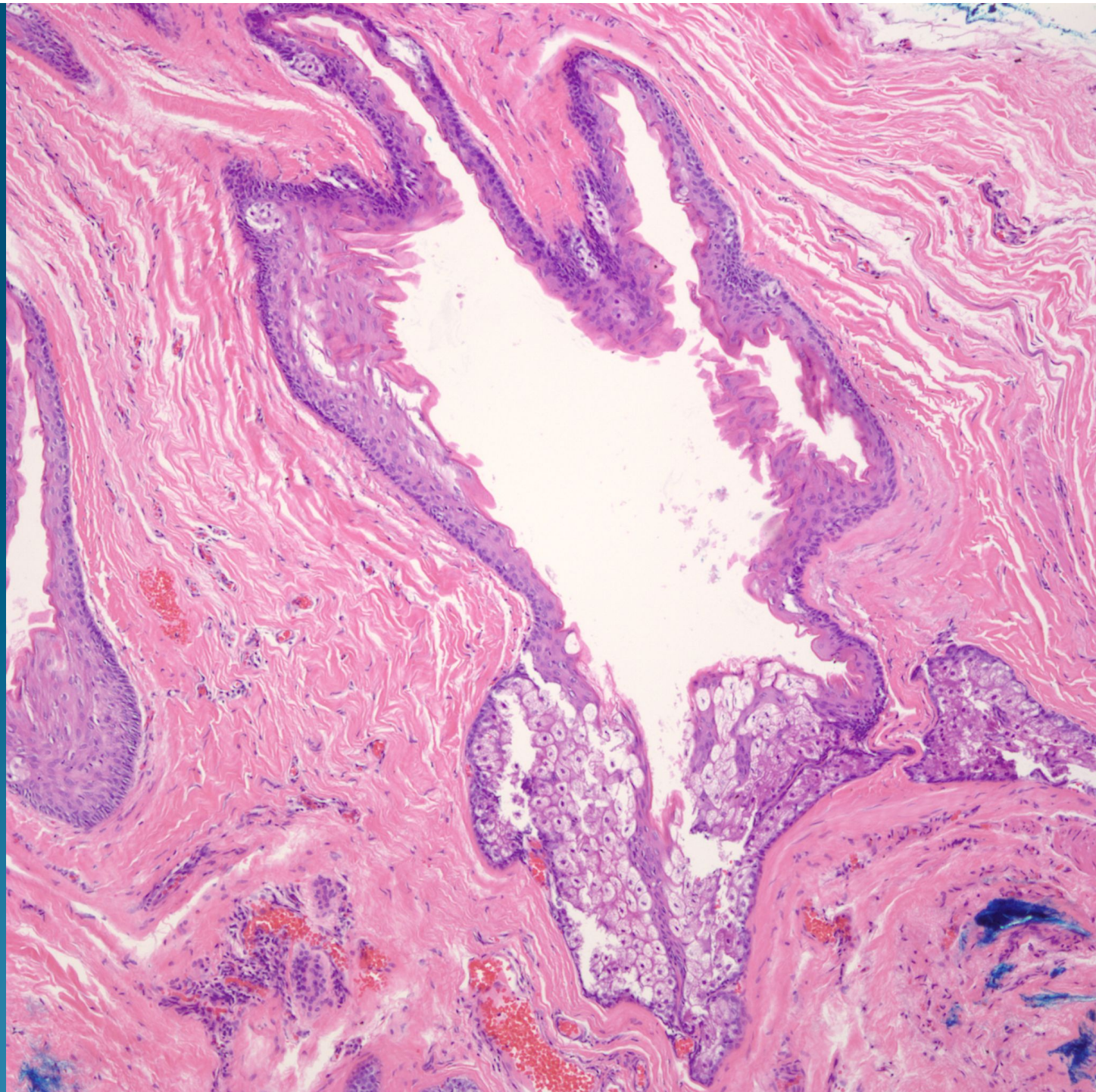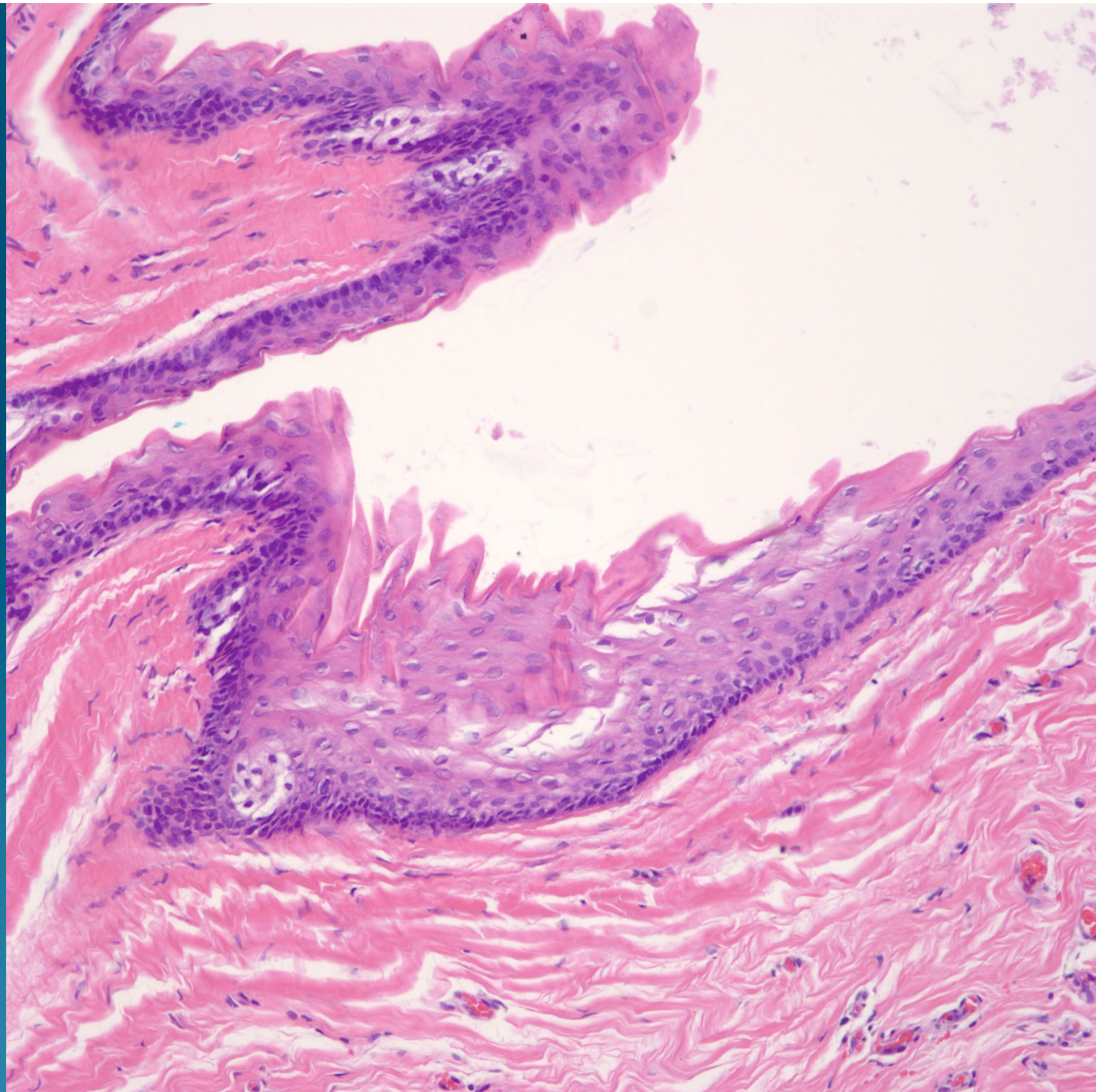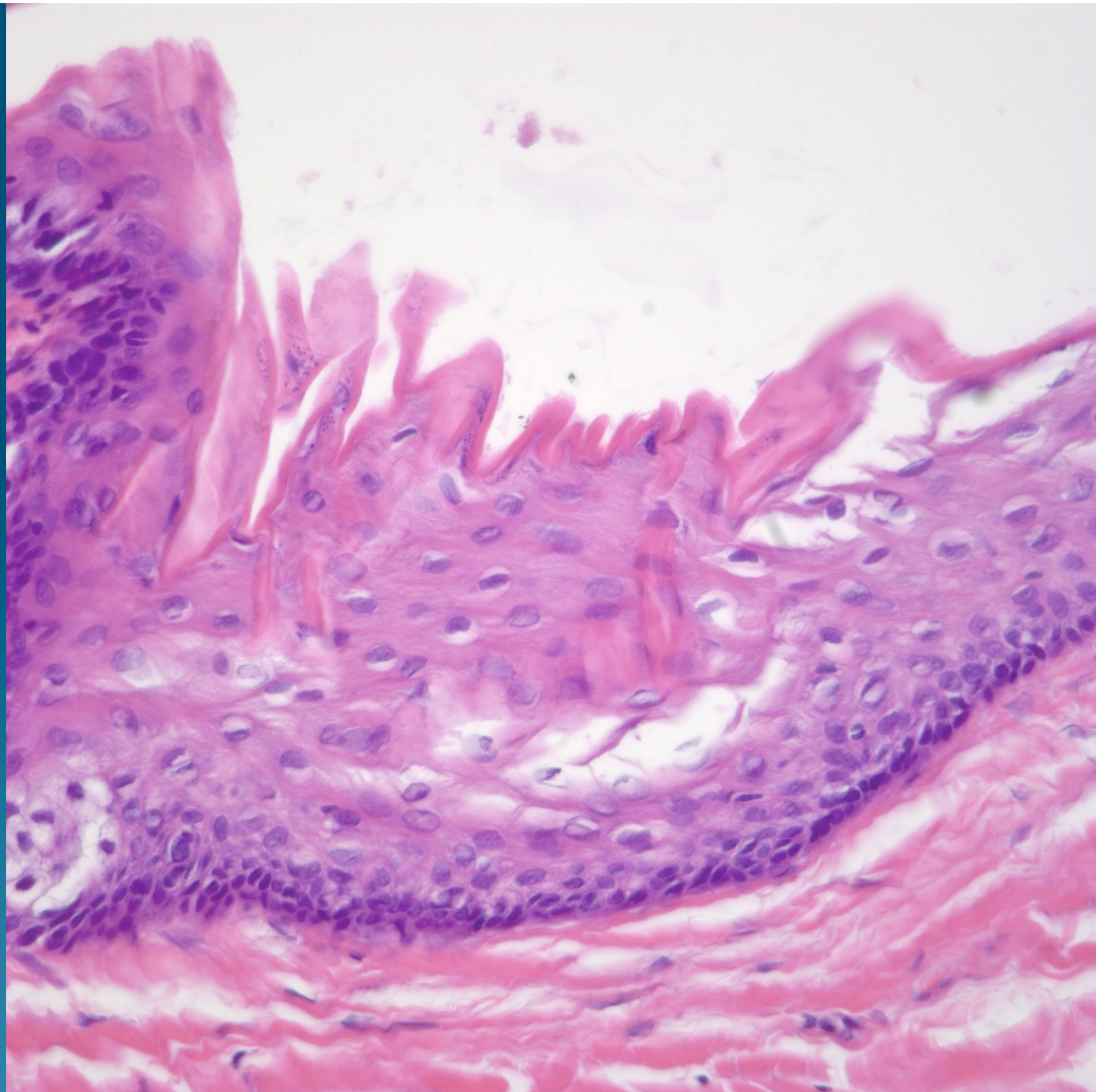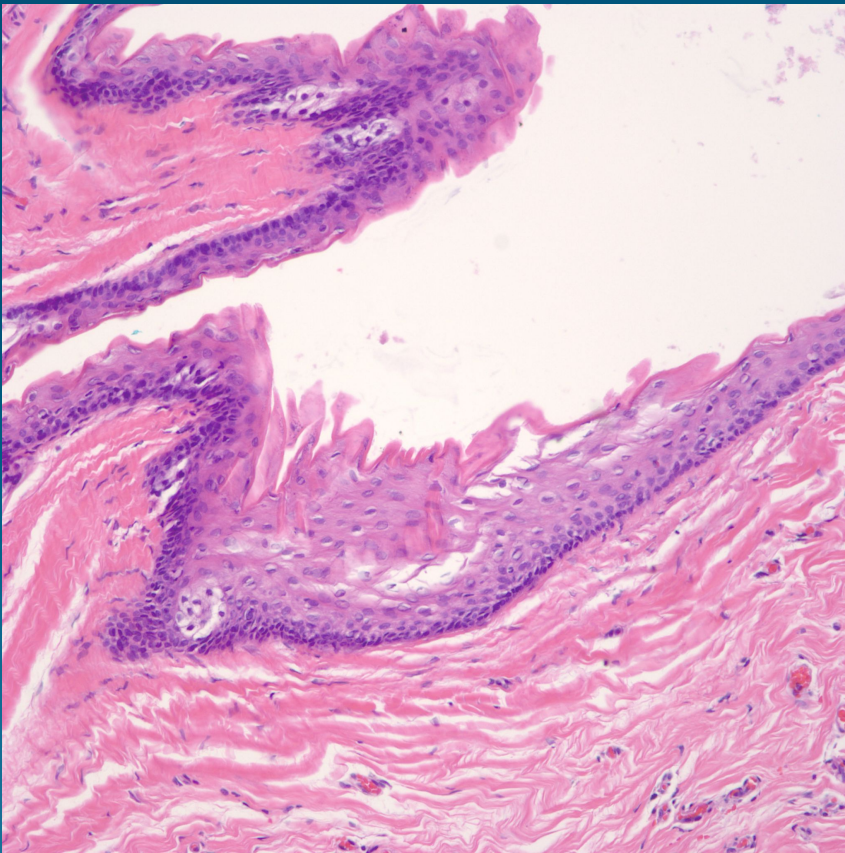


# What is the best diagnosis?

- A. Epidermal inclusion cyst
- B. Pilar (Isthmus Catagen) cyst
- C. Pilomatricoma
- D. Apocrine Hidrocystoma
- E. Steatocystoma

# Steatocystoma

# Pearls



- Epidermal cyst with “corrugated” eosinophilic cuticle like lining
- Sebaceous lobules embedded within epidermal wall
- No vellus hairs, confirm by polarized light examination